

## TYPES OF INCISIONS USED IN THE CATARACT SURGERY

D. CĂCIULĂ<sup>1</sup>, L. BRAN<sup>2</sup>, ELVIRA COJOCARU<sup>3</sup>

<sup>1</sup>„Dr. Constantin Papilian” Emergency Military Hospital, Cluj-Napoca, <sup>2</sup>Ophthalmology Clinic, University of Medicine and Pharmacy, Cluj-Napoca, <sup>3</sup>„Dr. Carol Davila” Central Clinical Emergency Military Hospital, București

**Keywords:** cataract, incision n

**Abstract:** The purpose of this article is to describe concisely the anatomy of the limbus and to present the types of incisions that can be done in order to enter the anterior chamber during cataract surgery. We present the classification of these incisions function of their localization and approach, and the main advantages and disadvantages related to the subjacent structures of the region, pointing out the tendencies of cataract incisions today.

**Cuvinte cheie:** cataractă, incizie

**Rezumat:** Introducere Acest referat general are ca scop o prezentare succintă a anatomiei limbului sclero-cornean și a tipurilor de incizii practicate în chirurgia cataractei pentru accesul în camera anterioară, clasificarea lor și caracteristicile acestora în funcție de localizarea lor și planurile în care se realizează. Se arată principalele avantaje și dezavantaje ale acestor aborduri în relație cu anatomia locală, și se punctează tendințele moderne în realizarea inciziilor în vederea operației de cataractă

At present, phacoemulsification became the standard procedure in cataract surgery, most of the surgeons preferring the clear cornea incision, unlike in the early '90s when it was used only by about 12% of surgeons. (1, 15) For the cataract surgery to become safer, the knowledge of the different types of incisions and the anatomy of the sclerocorneal limbus must be well mastered.

### The Anatomy of Limbus

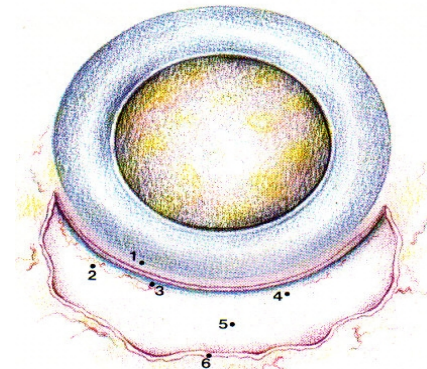
The sclerocorneal limbus is a structure that forms a ring around the cornea, representing an area that separates the cornea from conjunctiva, episclera and sclera. The sclerocorneal limbus can be divided into two zones: one including the corneal epithelium, the Bowman layer and part of the stroma, and a scleral one passing outside the Schlemm canal. In general the trabecular area, stretching from the scleral spur to the Schwalbe line, corresponds to the internal limits of the limbus. The conjunctiva firmly adheres to the sclera only at the limbic region. The connective tissue has numerous radial folds forming the palisades of Vogt which host the vascular and nervous network; the crypts of the limbic epithelium reach the depressions of the palisades, thing which offers some sort of protection for the limb stem cells.(1)

The vasculature of the limbus is derived from the episcleral branches of the anterior ciliary arteries, forming a shallow marginal plexus situated in the subepithelial connective tissue. In the area of the Vogt palisades there are two vascular layers: one at the surface made out of recurrent branches and one more profound, made of terminal branches. The veins follow the same route. There is a complex lymphatic system associated to the venous system. The innervation of the vascular plexus is provided by sympathetic fibers. At limbus level, there are nervous endings deriving from the first branch of the V<sup>th</sup> nerve through ciliary nerves, which then distribute to the cornea, sclera and subconjunctival tissue.

### Surgical Anatomy of Limbus

The identification of the limbus is very important for planning the surgical incisions and position.

**Picture no. 1. Visible details after taking-off conjunctiva: 1-clear cornea, 2- perilimbic vessels, 3-blue limbus, 4- surgical limbus, 5-sclera, 6-conjunctiva**



The anterior edge corresponds to the junction between the Tenon capsule, the conjunctiva and the cornea, being the area where the conjunctival vessels end and avascular cornea appears. A small ridge is visible at this level that corresponds approximately to the limit of the Bowman membrane. Making an incision perpendicular to the corneal surface at this level will open the anterior chamber before the Schwalbe line, so before the trabeculum.

Posterior from the edge of the limbus to there is an area called the “blue limbus”, a translucent zone, gray-blue, 0.2-1 mm wide, evidenced after taking-off the conjunctiva. The middle part corresponds to the anterior part of the trabeculum, represented by the Schwalbe line. Beyond the gray-blue area of the blue limbus there is a white area, about 1 mm wide, situated above the trabeculum. The transition line between the two areas corresponds to the end of Descemet membrane and to the Schwalbe line. Posterior edge of the “blue limbus” corresponds to the scleral spur and to the iris root. A perpendicular incision made at this level will pass through an area poorly vascularized and will enter the anterior chamber before the Schlemm canal, but posterior form the Descemet membrane, through a non-

<sup>1</sup>Corresponding Author: D. Căciulă, Emergency Military Hospital, Cluj-Napoca, <sup>2</sup>Ophthalmology Clinic, 22, Traian Moșoiu street, Cluj-Napoca, România, e-mail: icaciula@yahoo.com, tel +40-0744600677  
ACTA MEDICA TRANSILVANICA Martie 2010; 2(1):161-163

## CLINICAL ASPECTS

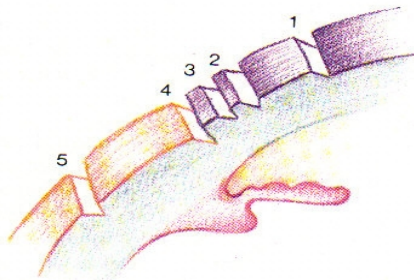
functional portion of the trabeculum. The limbic area is wider in the upper and lower quadrants. In the nasal and temporal regions the limbus is narrower and blue-gray area may be absent.

### Types of incisions made to enter the anterior chamber

The incision is influenced by three basic factors: the shape of the cutting tool, the way the surgeon directs the instrument through the tissues and the particular tissue properties.

The incisions that require the opening of the anterior chamber are classified according to their position and plan of approach.

**Picture no. 2. Classification of incisions by position (1): 1.Cornean; 2.Anterior limbus; 3.Middle limbus; 4.Posterior limbus; 5.Scleral**



Classification incisions made by plane of achievement: vertical, oblique, two planes, three planes, four planes, oblique reverse.(1)

### Characteristics of incisions depending on their position

#### i.) incision in clear cornea

This type of incision has the advantage of being located away from the root of the iris, thus avoiding the iris prolapse and irido-corneal synechia formation. Being made in an avascular area, it does not bleed during surgery. It ensures a good visibility and allows good handling of the core, and a better approach to cortical remains in the superior regions. This incision should be slightly larger than one limbic or scleral incision in order to achieve the same workspace. In case of a clear cornea incision that's too tight the surgeon will cause excessive rotation of the eye with phacoemulsification probe. Also a very large incision will lead to the instability of the anterior chamber. The suture of such incisions should be made carefully to avoid excessive postoperative astigmatism.(1,7,9)

#### ii.) limbic incision

This type of incision can be practiced in the anterior part of the limbus, into the cornea, in its middle part or in the posterior part, toward the sclera. The difference between these sites is mainly the degree of vascularization of the tissue that decreases from the sclera to the cornea. It is not recommended to penetrate the anterior chamber through the posterior part of the limbus because the iris prolapse can occur with its incarceration in the wound and at the same time the trabeculum is torn. Damage to the trabeculum will cause angular synechia and scarring which will change the chamber angle architecture. (10) Oblique incisions are preferred, or in two plans, that enter into the anterior chamber at the cornea level.

#### iii.) scleral incision

The presence of the ciliary body makes it impossible to achieve this incision in a single plan, therefore usually one makes first a scleral tunnel by a cut in three planes, which starts perpendicular to the sclera, 2-3 mm posterior to the limbus, then it continues through sclera parallel to its plans to the surgical limbus, ensuring the entry into the anterior chamber at the cornea level. This ensures a good sealing incision, allowing the

surgeon to perform an easy suture. It induces a minimal postoperative astigmatism because the deformation of the cornea is reduced, being further stabilized by the limbus ring. It has the advantage that it does not penetrate the Bowman membrane and it is located away from the root of the iris and from the angle structures. An incision that is too large will reduce the scleral rigidity and may lead to anterior chamber collapse during surgery.(2,5)

### The main types of incisions used in cataract surgery by phacoemulsification

#### i.) Single plane incision

*The perpendicular limbic incision* is done in the anterior part of the limbus. It has the disadvantage of slow healing and it requires suturing, also maintaining a stable anterior chamber is difficult, because the instruments which perform the aspiration and irrigation separate of the wound edges, reducing the tightness required to have a good chamber. (14)

*Oblique limbic incision* is usually practiced in the middle part of the limbus. The incision is deep, on the desired length, after a plane that made an angle of  $110^\circ$  with the cornea. It guarantees a comfortable access into the anterior chamber, an excellent sealing and it's easily sutured with a few threads, which are buried under a conjunctival flap. The contact area between the wound edges is greater, thus placing instruments in the eye does not cause an immediate separation of wound edges, thus ensuring a good stability of the anterior chamber. It bleeds a little more than the perpendicular incision because of its more posterior location, but the richer vasculature provides a faster healing. The main disadvantage of this incision is the increased resistance to cutting by the limbic tissue.(7)

#### ii.) Two planes incision

*The angled limbic incision* is made at the level of the cornea, limbus or sclera- in the vicinity of the limbus. It is situated in two planes, one perpendicular to the oblique one, which makes an angle of  $110^\circ$  with the surface of the cornea. (12) The incision ensures the maintenance of a constant pressure and depth of the anterior chamber during the phacoemulsification operation. The aspiration of the lens cortex and the insertion of an artificial crystalline is convenient and the suture is not usually necessary.

*The reverse corneal incision* begins at the level of clear cornea 1-2 mm in front of the limbus, the first incision being driven centrifugally, obliquely and profound. The incision is made over a length of about  $\frac{3}{4}$  of the thickness of the cornea. (12) The opening of the anterior chamber is made with the same instrument by an oblique incision, but preferably perpendicular to the corneal surface.(4) There will result an incision with an excellent capacity of self-sealing, which does not require suturing, inducing a minimal degree of postoperative astigmatism. It has the advantage of avoiding limbic structures, being very useful for eyes that have previously suffered a filtering operation. It has the disadvantage of being technically more difficult to run.

#### iii.) Three or four plans incision

The incision in four planes involves the preparation of a conjunctival flap orientated toward the "cul-de-sac". The first (or second plane) is perpendicular to the cornea and the incision is carried out almost in clear cornea. The second (or third) plane is incised tangentially at the corneal surface, through the corneal lamellae, on a length of 1-2 mm. The anterior chamber will be opened by a perpendicular incision. This type of incision has the advantage of being perfectly self-sealing and preserves best the anatomical structures because the curve of the first perpendicular incision may differ from that of the second perpendicular incision which may follow the internal margins of

the limbus. Another big advantage is that the steps needed to achieve the incision can be easily corrected, and the small incision errors do not have significant consequences.(11,14)

### **Current trends of microincisions used in phacoemulsification**

The future belongs to the microincisions (1.8 - 2 mm) because of the advantages they offer: easy to perform at clear cornea level, they prevent the expulsive haemorrhage, surgical trauma is minimal, healing is more rapid, reduced hospitalization time, VA recovered quickly after surgery, they do not require suturing, postoperative induced astigmatism is minimum, better surgical control of astigmatism, iris prolapse is much less common, they serve to maintain intact the areas necessary for a possible glaucoma intervention.(3,6,8,13)

### **REFERENCES**

1. Buratto L, Iori M: Incisions, in *Incisions and sutures in cataract surgery*, Milano, Ed. Fogliazza, 1993;3-59.
2. Burkhard Dick H, Schwenn O, Krummenauer F, Krist R, Pfeiffer N. Inflammation after Sclerocorneal versus Clear Corneal Tunnel Phacoemulsification, *Ophthalmology* 2000;107:241–247.
3. Centurion, Buzard K. Small incision in cataract surgery, *Highlights of ophthalmology*, German edition, 1999;27:38-39.
4. Charleux J. Reverse corneal incision in cataract surgery, in Buratto L. *Extracapsular cataract microsurgery*”, Milano, Ed. Centro ambrosiano microchirurgia oculare, 1989;303-305.
5. Gross RH, Miller KM. Corneal astigmatism after phacoemulsification and lens implantation through unsutured scleral and corneal tunnel incision, *Am J Ophthalmol* 1996;121:57-64.
6. Kaykcioglu O. Clear corneal incision with trypan-blue-coated blades, *J Cataract Refract Surg*, 2007;33:351-2.
7. Kraff CR, Kraff MC, Krupin T, Kolker AE, Rosenberg L. *Complication in ophthalmic surgery*, 2nd ed, Mosby, 1999;58-59.
8. Kurz S., Krummenauer F, Pia G, Pfeiffer N, Burkhard D. Biaxial Microincision versus Coaxial Small-Incision Clear Cornea Cataract Surgery, *Ophthalmology* 2006;113:1818–1826.
9. Masket S, Tennen DG. Astigmatism stabilization of 3.0mm temporal clear corneal cataract incision, *J Cataract Refract Surg*1996; 22:1451-1455.
10. Monica L, Daniel A. Nine-Year Safety with Self-sealing Corneal Tunnel Incision in Clear Cornea Cataract Surgery, *Ophthalmology* 2005;112:985–986.
11. Percival P, Beare N. Clear cornea sutureless phacoemulsification and astigmatic decay after two years, *Eye* 1997;11;381-384.
12. Ricci A. Corneal opening for cataract operations. *Extracapsular cataract microsurgery*, Milano, Ed. Centro ambrosiano microchirurgia oculare, 1989;284-292.
13. Tejedor J, Murube J. Choosing the Location of Corneal Incision Based on Preexisting Astigmatism in Phacoemulsification, *Am J Ophthalmol* 2005;139:767–776.
14. Tsuneoka H, Takahashi Y. Scleral corneal 1-plane incision cataract surgery, *J Cataract Refract Surg* 2000;26:21–25.
15. Zheng L, Merriam JC, Zaider M. Astigmatism and visual recovery after large incision extracapsular cataract surgery and small incision for phacoemulsification. *Trans Am Ophthalmol Soc*, 1997;95:387-410.